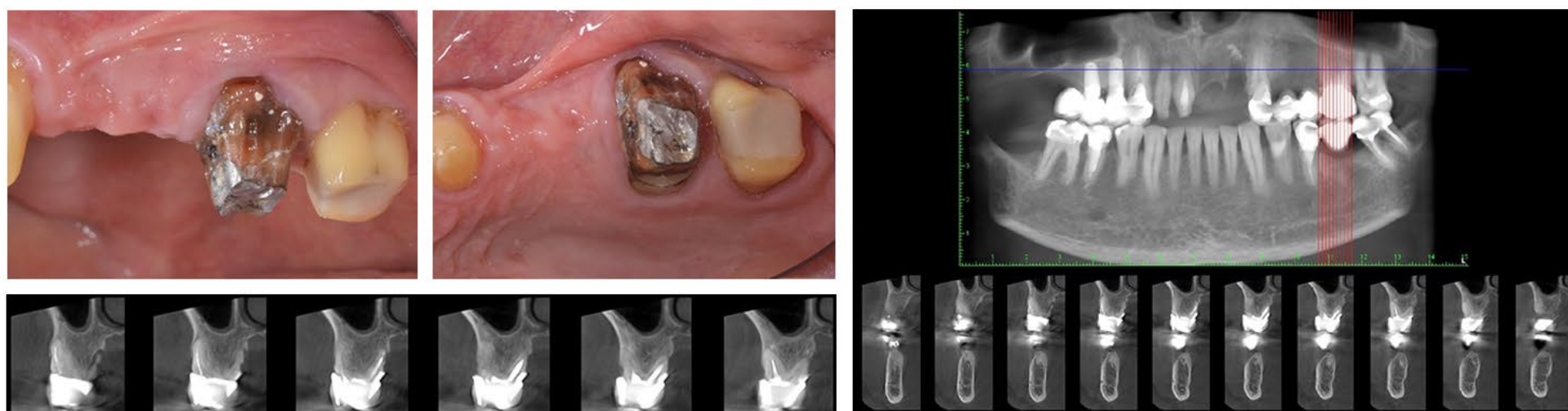
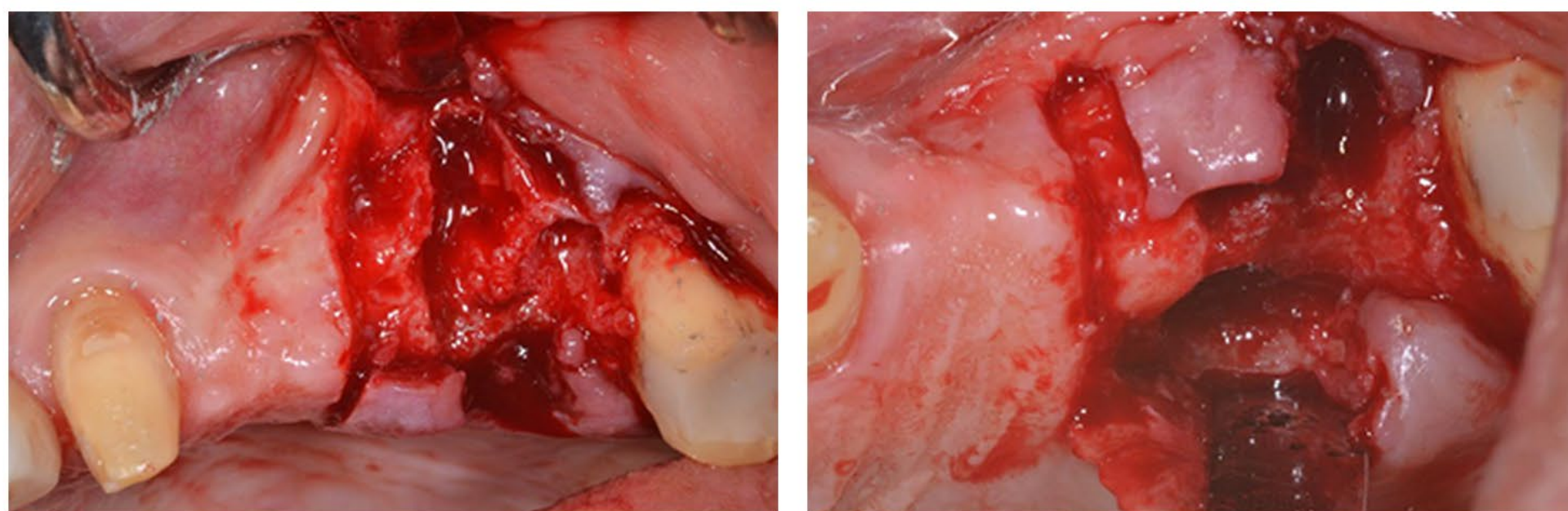


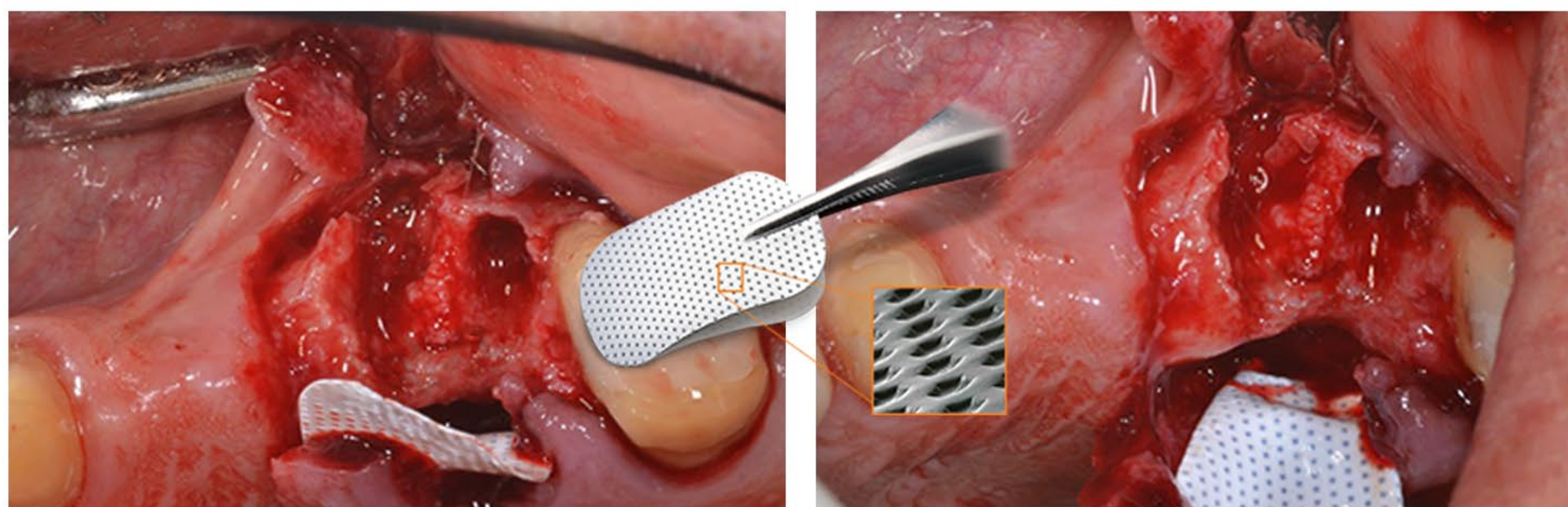
CLINICAL CASE: SOCKET AUGMENTATION UPPER MOLAR WITH NOVABONE



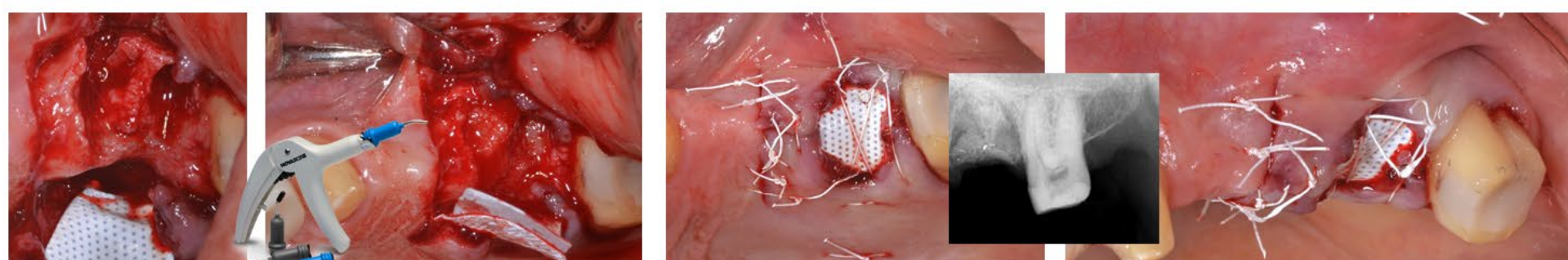
Complete palatal socket wall resorption Partial buccal socket wall resorption.



Complete resorption of the palatal wall and mesio vestibular

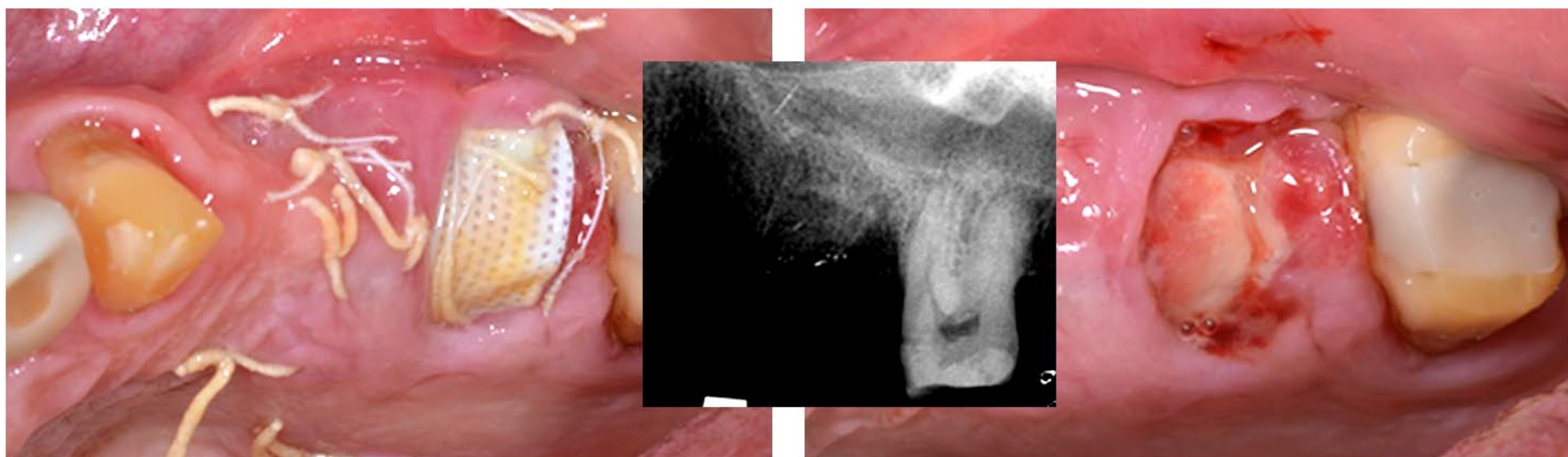


Cytoplast TXT 20012x24 membrane stabilized with a suture to the palatal flap

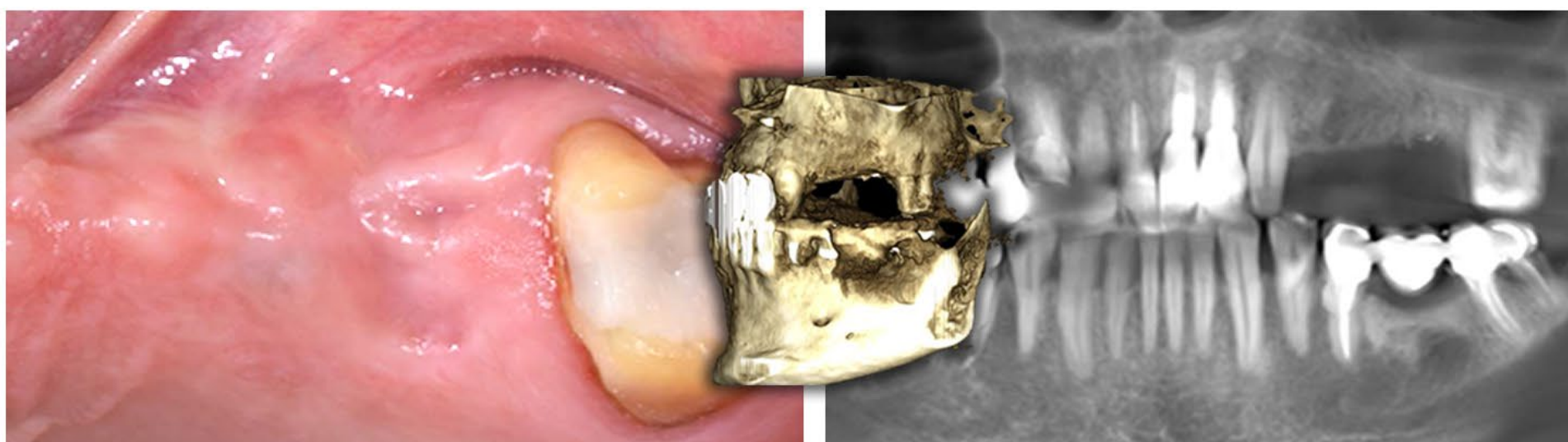


Since the bone defect was so extensive, a second membrane (Vitala 20x30) was inserted below the PTFE one, to cover the NovaBone dental Putty graft along the entire defect (buccal, coronal, palatal. Only the PTFE membrane remained exposed

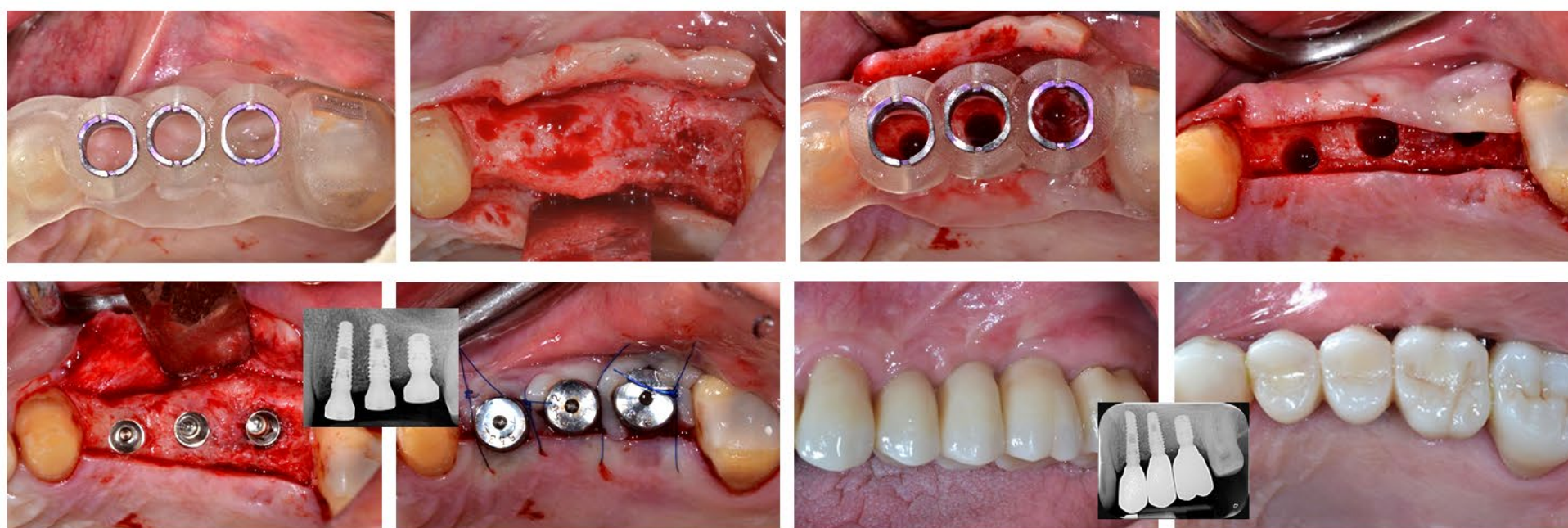
CLINICAL CASE: SOCKET AUGMENTATION UPPER MOLAR WITH NOVABONE



3 weeks. The PTFE membrane was removed and the Vitala membrane was visible.



6 months later, the tissue is completely healed 3 weeks. The PTFE membrane was removed and the Vitala membrane was visible.
6 months later, the tissue is completely healed



Implants placed trough guided surgery.

Final Restorations. Prosthetics by Dr. Mattei. Fondi, Italy



Dr. Fabrizio Belleggia, DDS

Dentistry and Dental Prosthesis,
Catholic University of Sacred Heart. Rome, Italy
Post graduate degree in oral surgery.
University of Rome "Tor Vergata"

NOVABONE®

Best outcome. Back to life.

