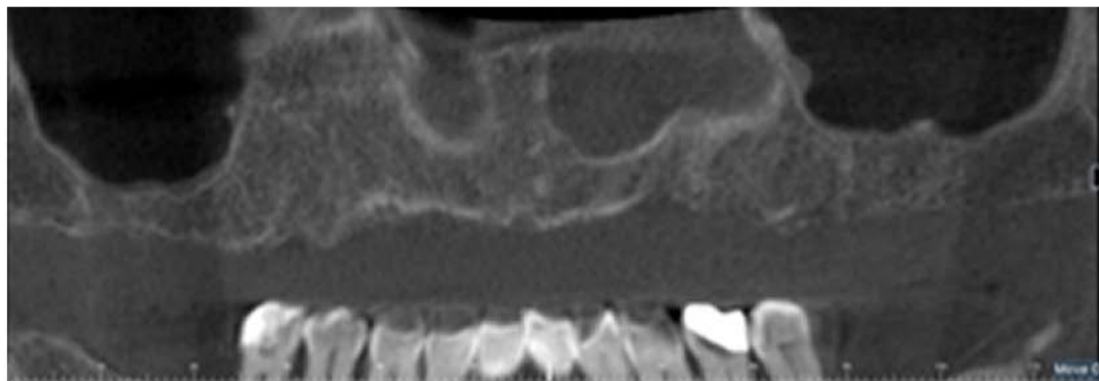
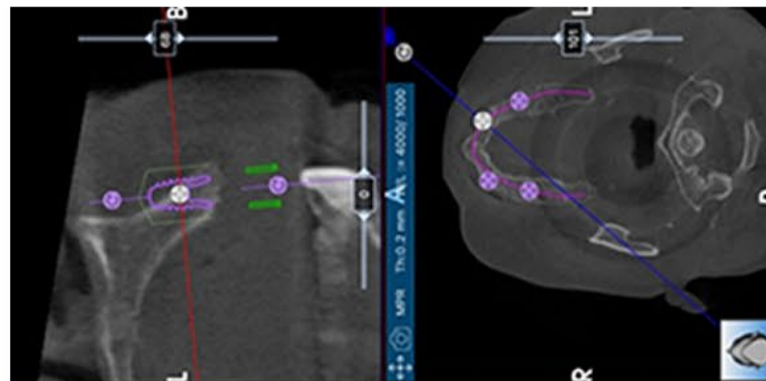


CLINICAL CASE: IMPLANT-SUPPORTED PROSTHESIS WITH DOUBLE BAR

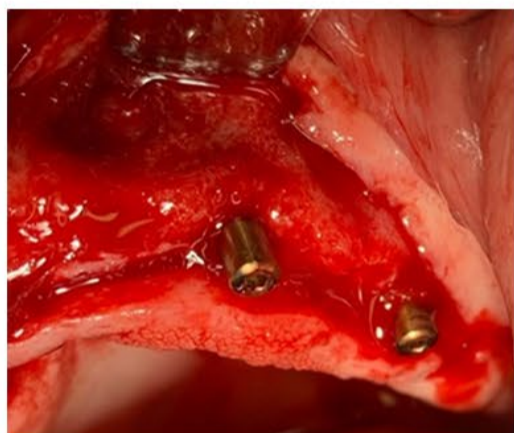This 61-year-old healthy woman has had a history with periodontitis, and she lost all her upper teeth. She was not happy with her prosthesis and wanted a better solution.



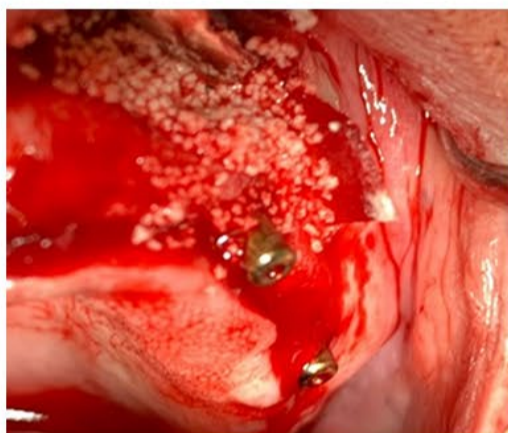CBCT of upper jaw.



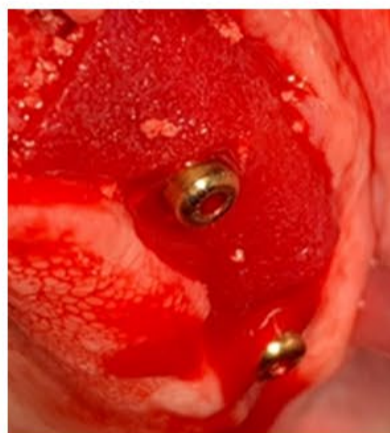To get a parallel implant placement, the cbt shows there is to little bone buccally



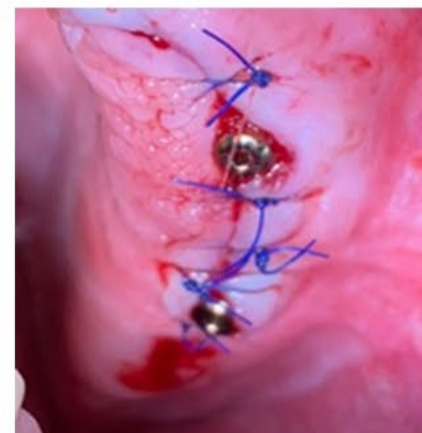Situation after implant placement (Blue diamond 3.3mm diameter NC 10mm length)




GBR using Novabone Morsels



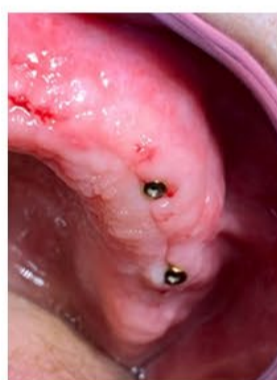Placement of Osseoguard membrane Biomet 3i



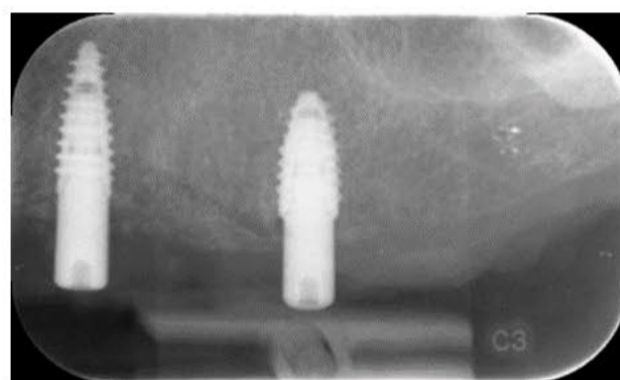
Clinical situation after suturing



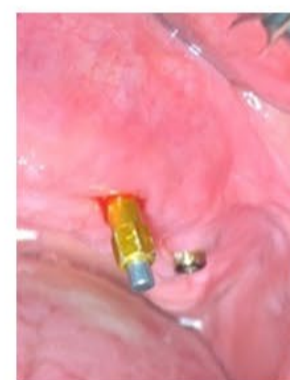X Ray of implants after placement



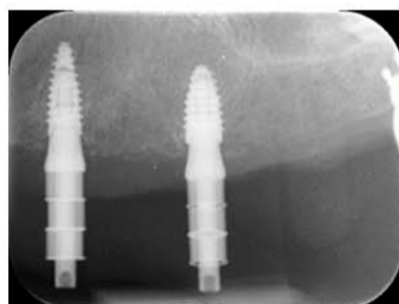
Situation after two weeks, sutures removed



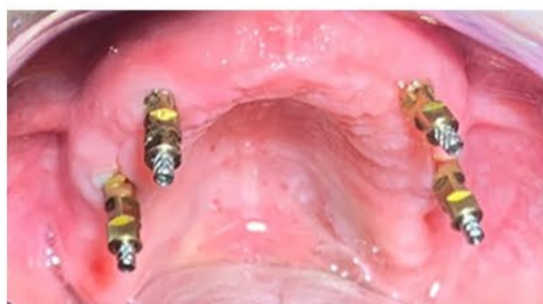Xray after three months



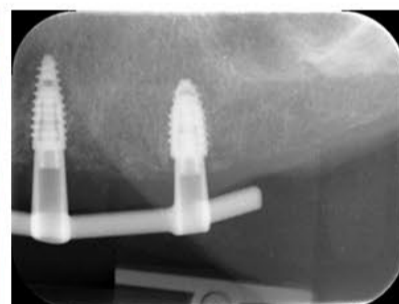
Situation after three months, ISQ measurement 73



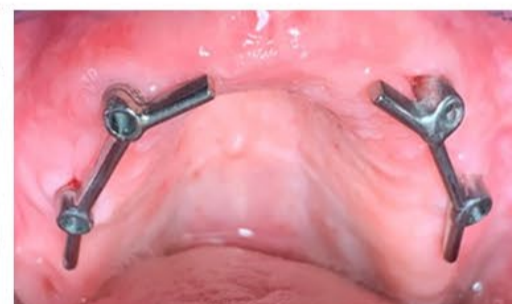Xray checking if impression posts are fitted correctly



Impression posts in place



Xray of bar placed



Bars placed



Dr. Maarten J. Boogaard, DMD

Dental Medical Degree University of Amsterdam
Masters of Periodontology University of Alabama (UAB)
Private practice in Amsterdam and Amstelveen,
The Netherlands, where he specializes in Implantology.

