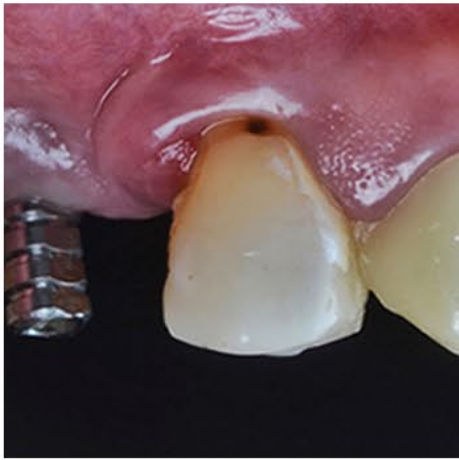
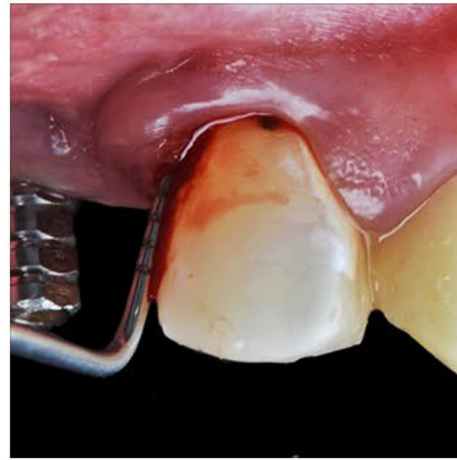

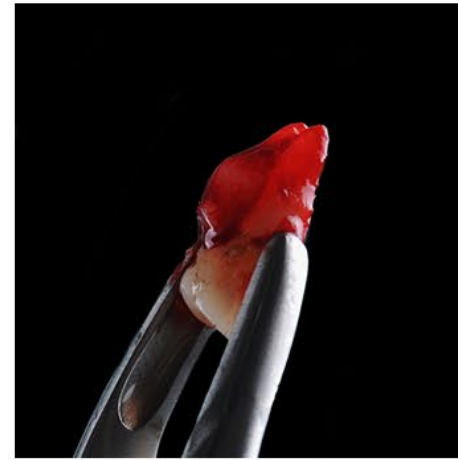
SOCKET PRESERVATION WITH NOVABONE PUTTY: STEP BY STEP



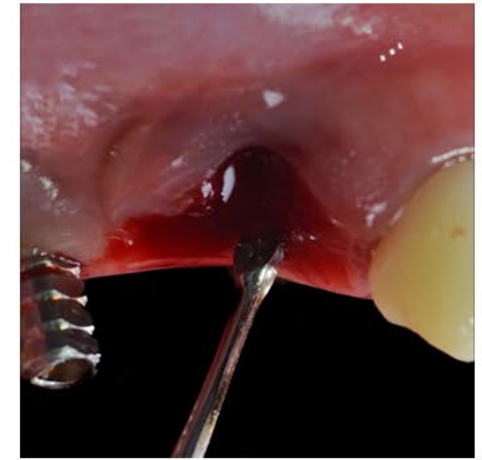
Initial situation



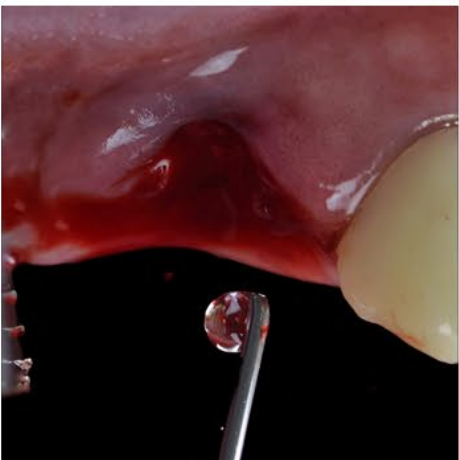Probing periodontal pocket



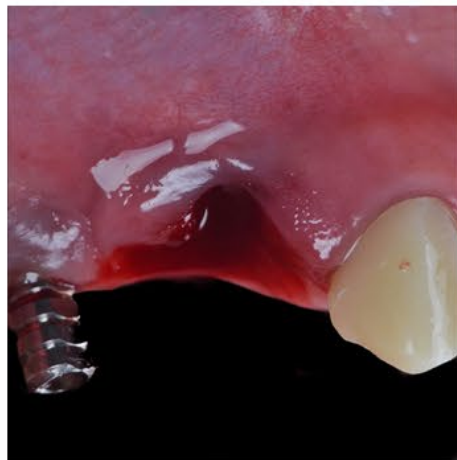
Extraction tooth 3.5




Cleaning of the site



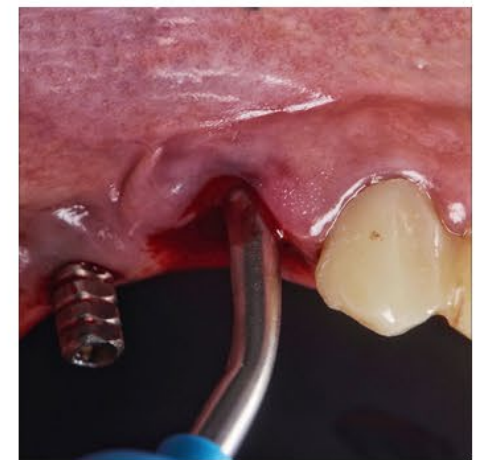Cleaning of the site



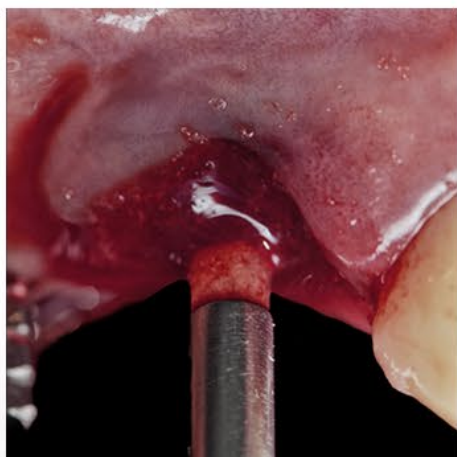Site clean and ready to graft



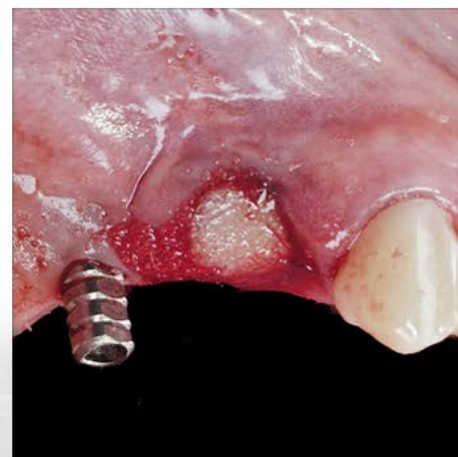Novabone putty cartridge



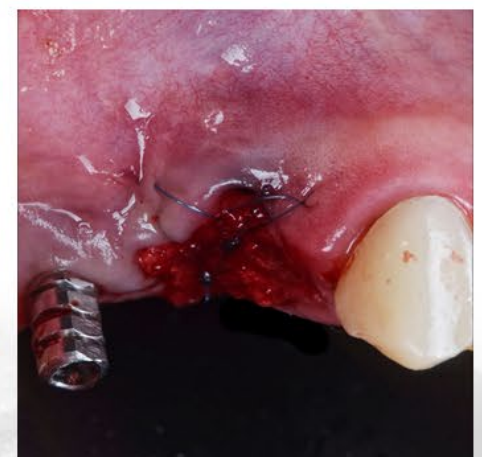Placement of the putty



Placement of the putty



Putty placed into the socket



Procedure complete after suture



Dr. Andres E. Ponce, DDS

DDS La Frontera University. Temuco, Chile
Prosthodontist Del Desarrollo University. Concepción, Chile
Private Practice Simetrica and Concept Clinic. Temuco, Chile