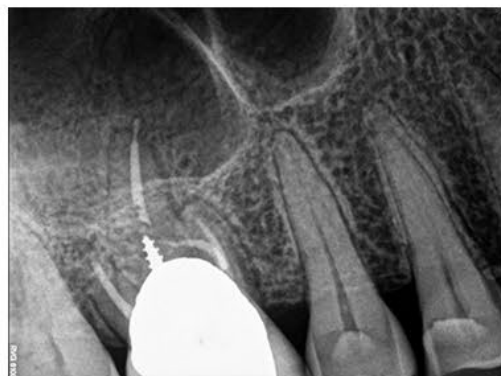
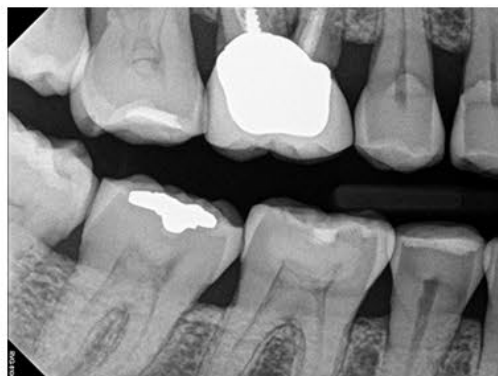
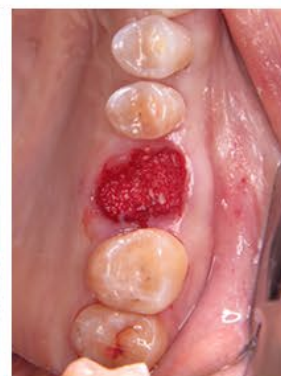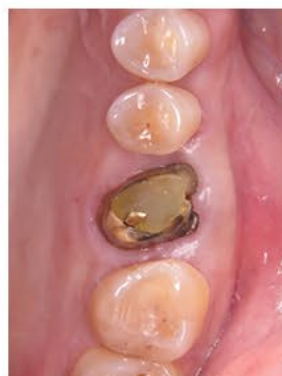SINUS LIFT PROTOCOL WITH NOVABONE PUTTY - 4 YEARS FOLLOW UP



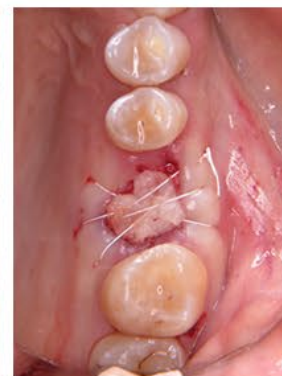Initial situation - x rays



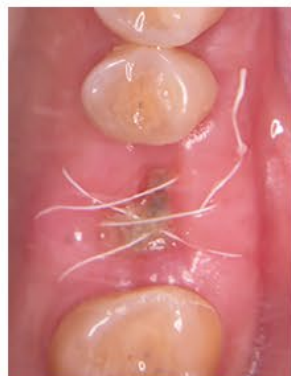Initial situation



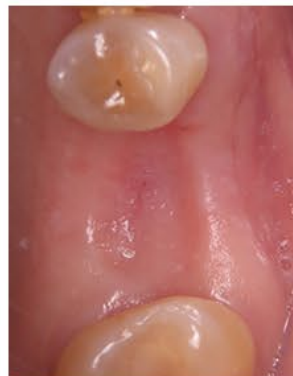Graft



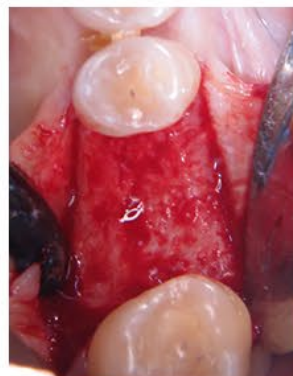PRF



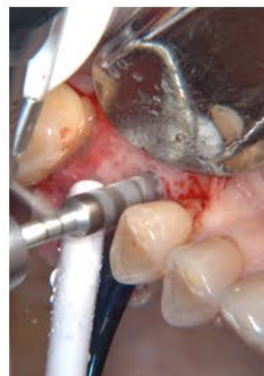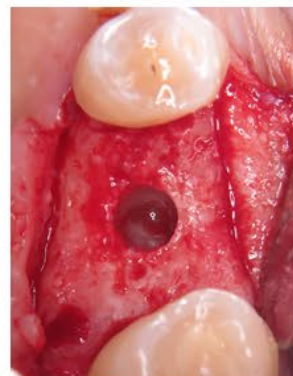
2 weeks



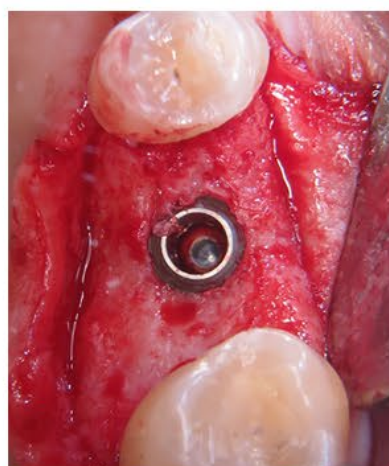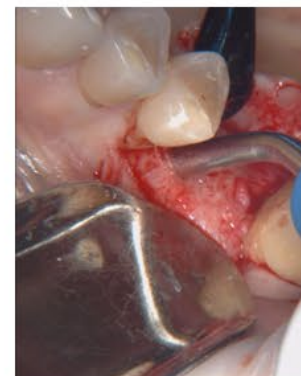3.5 months



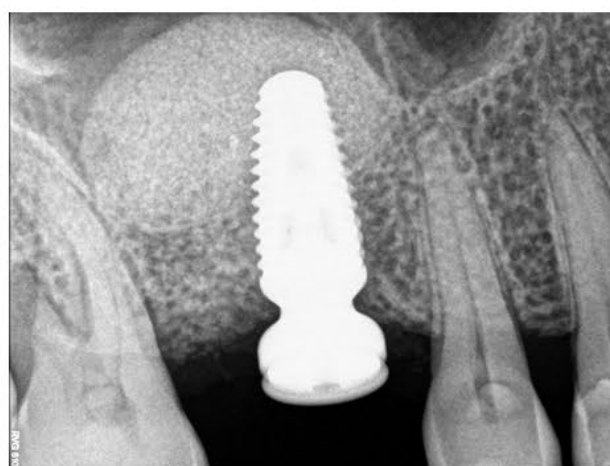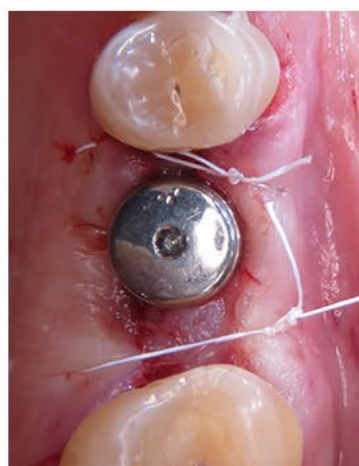Sinus lifting access



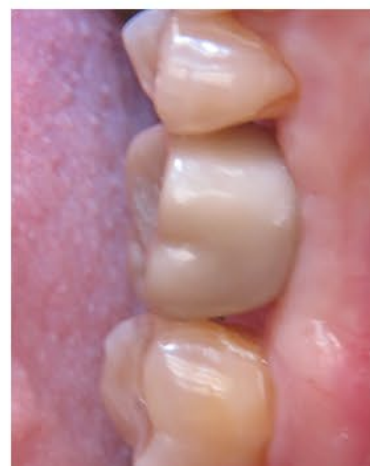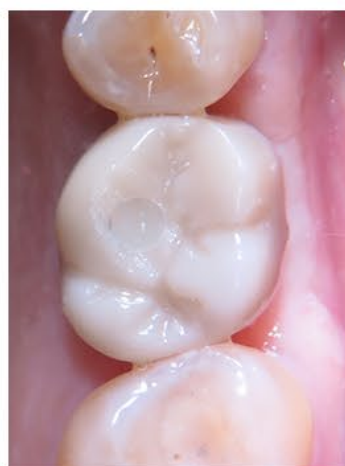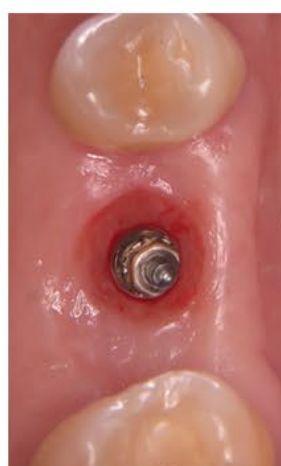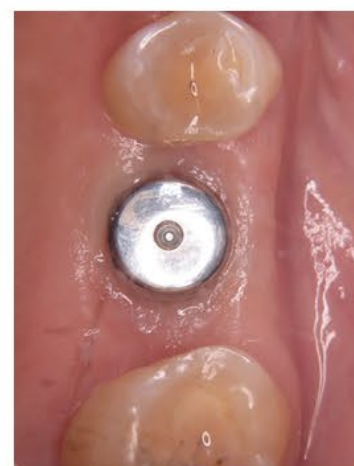Bone added incrementally combined with Versah burst



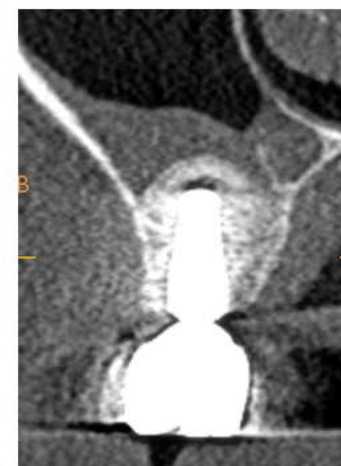Implant placement with high stability / ISQ



3 months post operative



Final restoration / Soft tissue response



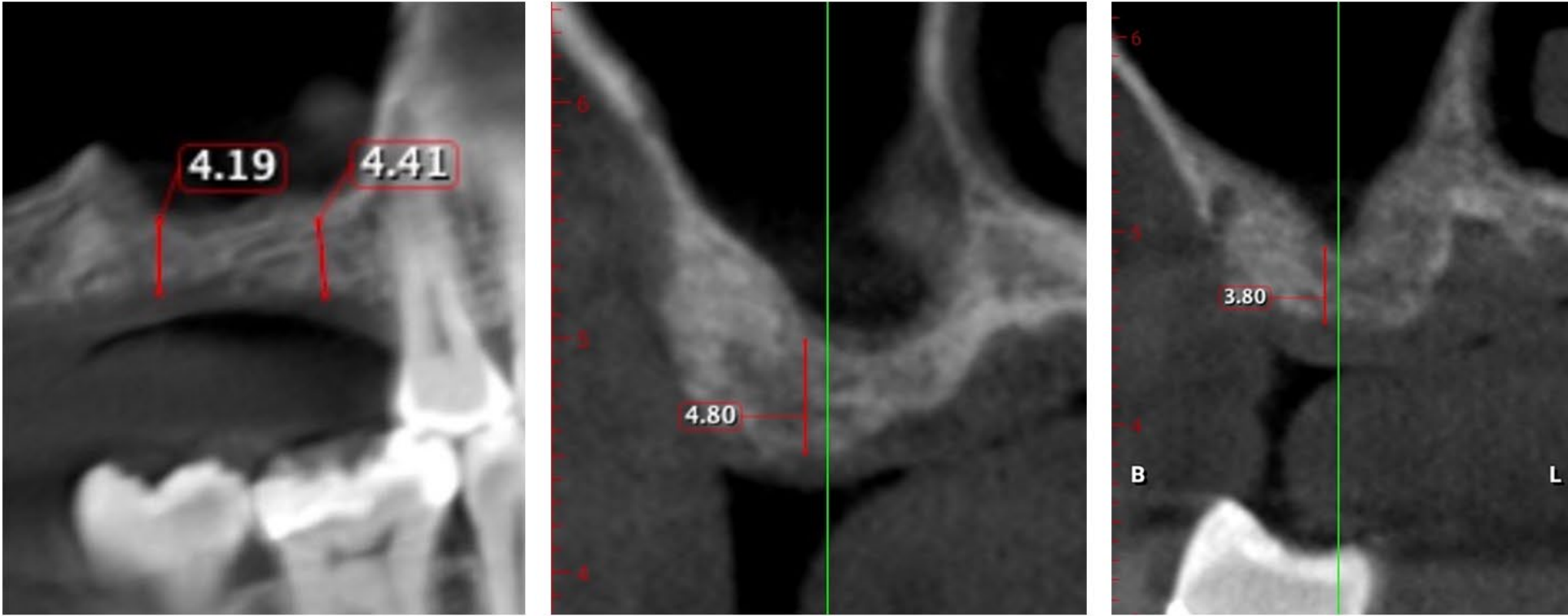
4 year PO CBCT



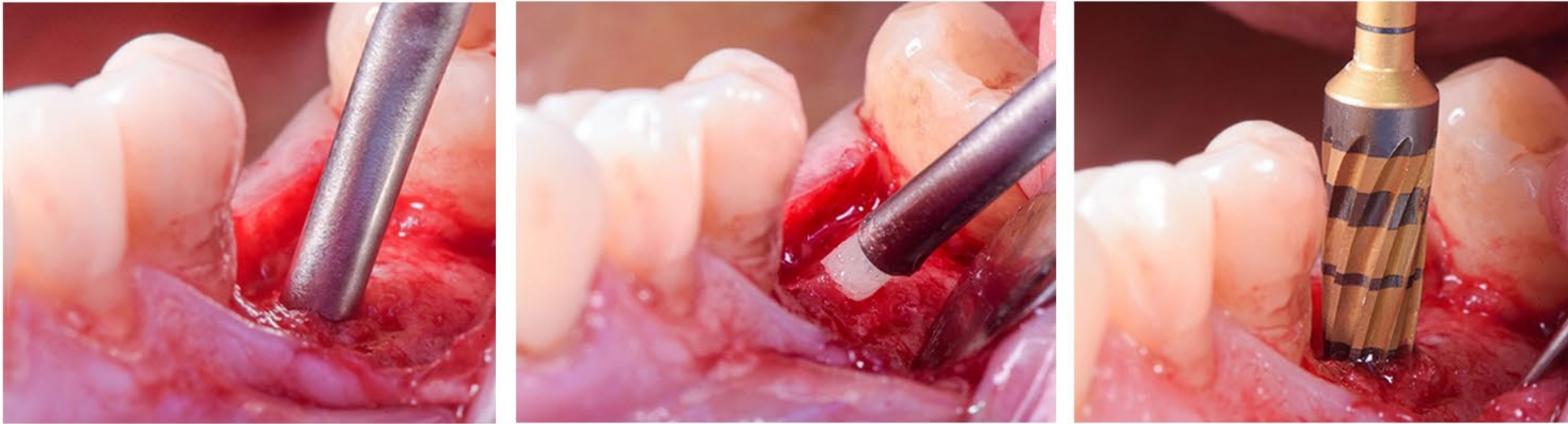Dr. Isaac Tawil, DDS

Masters degree in Biology from Long Island University
DDS from NYU College of Dentistry
Diplomat International Academy Dental Implantology
Diplomat International Academy for Dental Facial Esthetics
Fellow International Congress of Oral Implantology
International speaker and

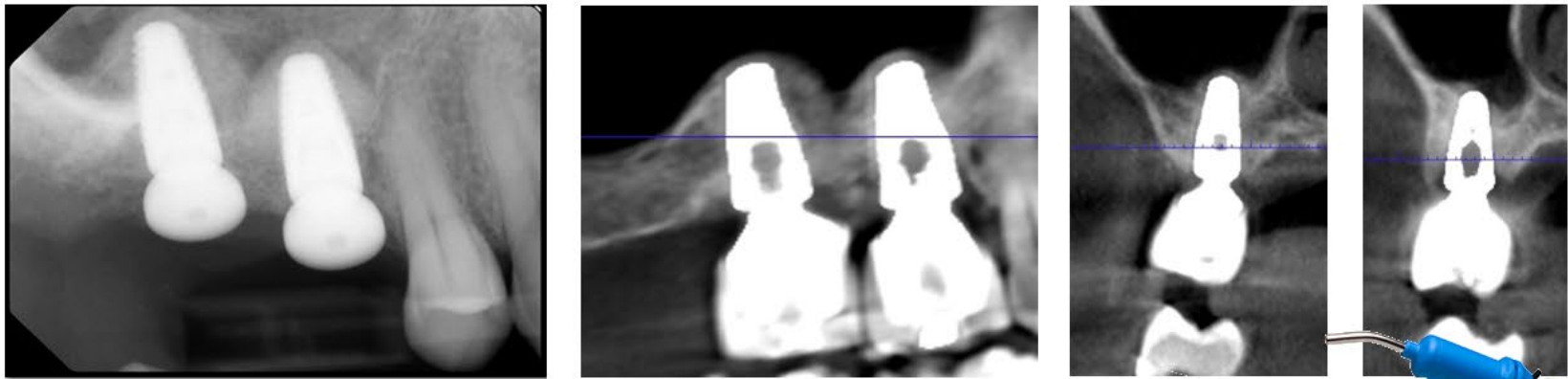
CLINICAL CASE SINUS LIFT AND IMPLANT PLACEMENT WITH NOVABONE PUTTY



CBCT initial situation



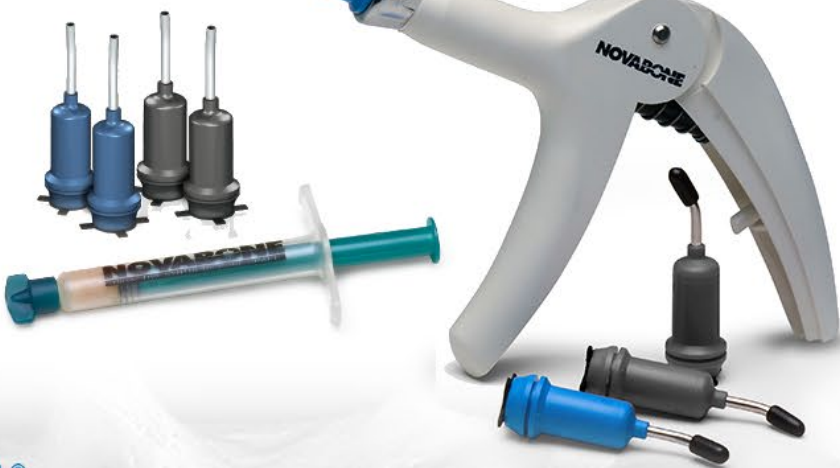Combined use of Novabone Putty and Versah sistem for osseodensification for the sinus lift and implant placement final result




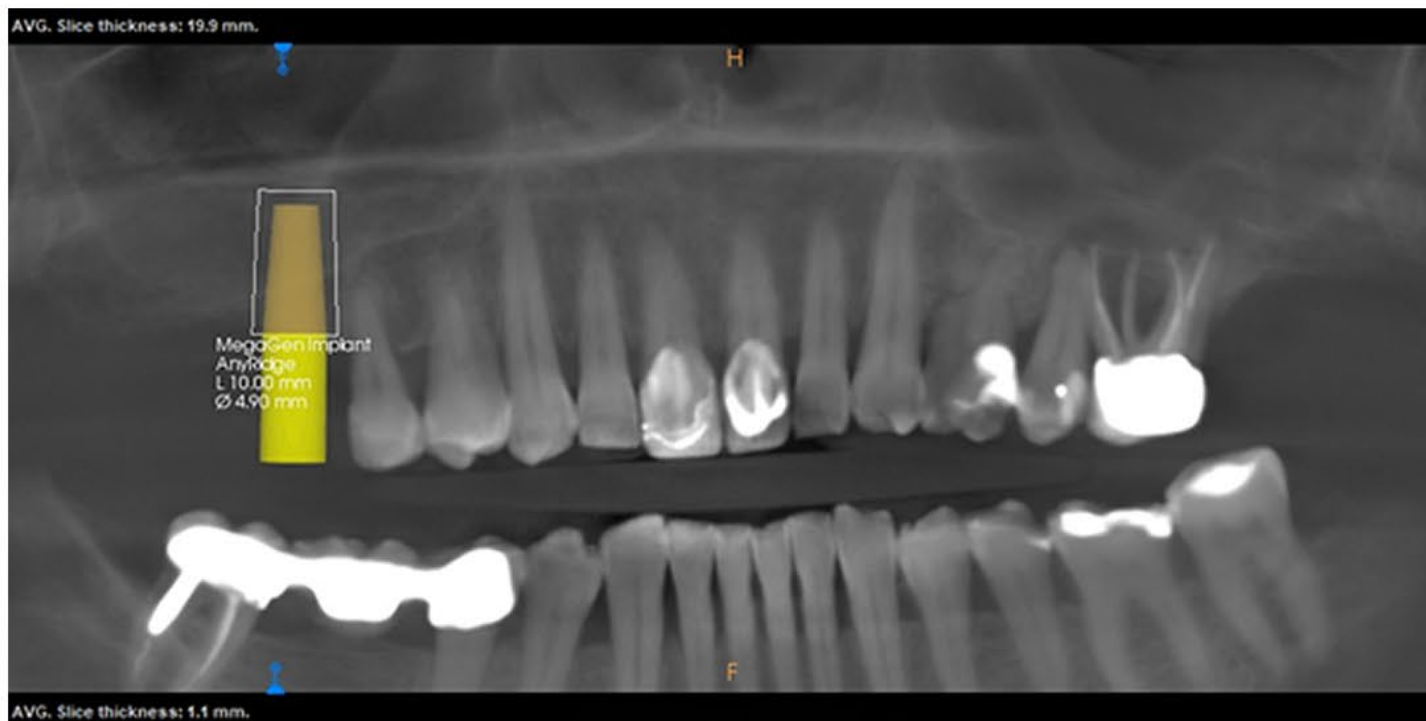
CBCT follow up final situation



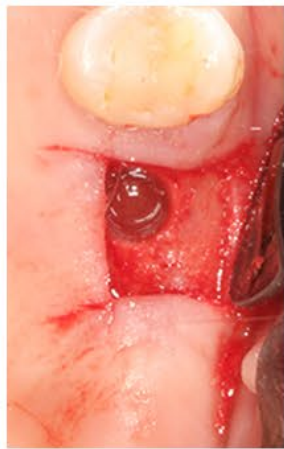Israel Puterman, DMD, MSD
Periodontist
Implants DC Private Practice



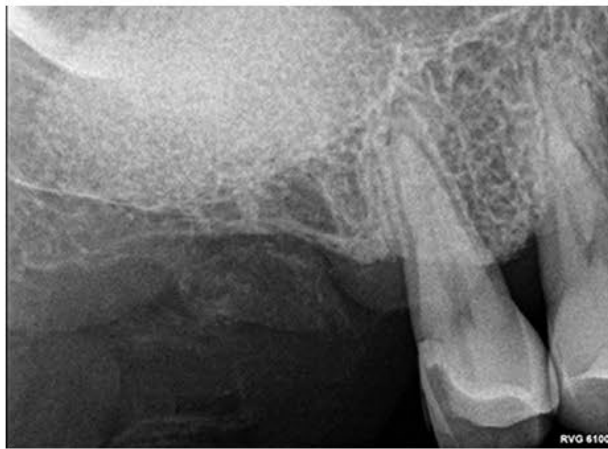SINUS LIFT PROTOCOL WITH NOVABONE PUTTY



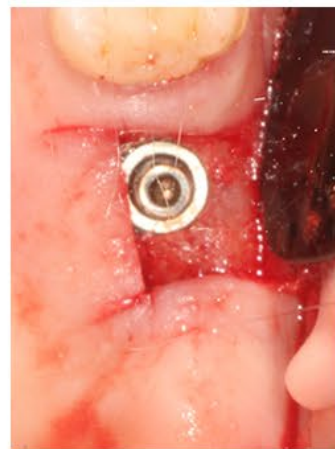
Initial situation - CBCT and planning implant placement



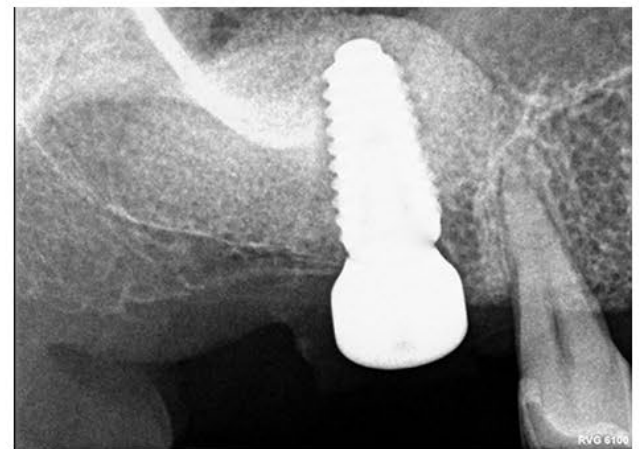Sinus lifting access



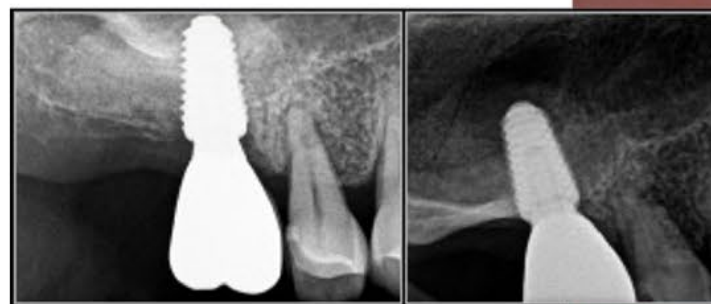Sinus lift executed



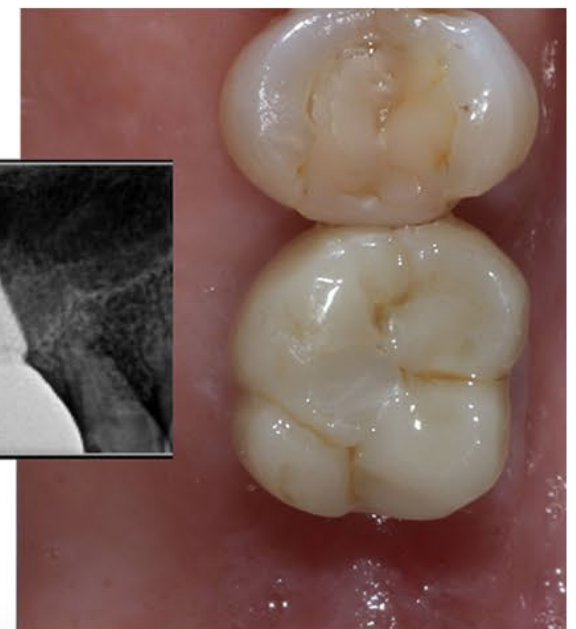Implant placement



Radiographic follow up



Final restoration / Radiographic follow up



Dr. Isaac Tawil, DDS

Masters degree in Biology from Long Island University
DDS from NYU College of Dentistry
Diplomat International Academy Dental Implantology
Diplomat International Academy for Dental Facial Esthetics
Fellow International Congress of Oral Implantology
International speaker and